

VALORACIÓN MEDIANTE CTMD DE ABSCESO AÓRTICO POST- ENDOCARDITICO Y ANATOMIA CORONARIA, PREVIO A CIRUGIA.

Virginia Álvarez Asiain. Amaya García de la peña Urtasun.
Cristina del Bosque. Servicio de Cardiología Hospital de
Navarra.

Saioa Solchaga. Mercedes Ciríza Esandi. Servicio de
Radiodiagnostico. Hospital de Navarra

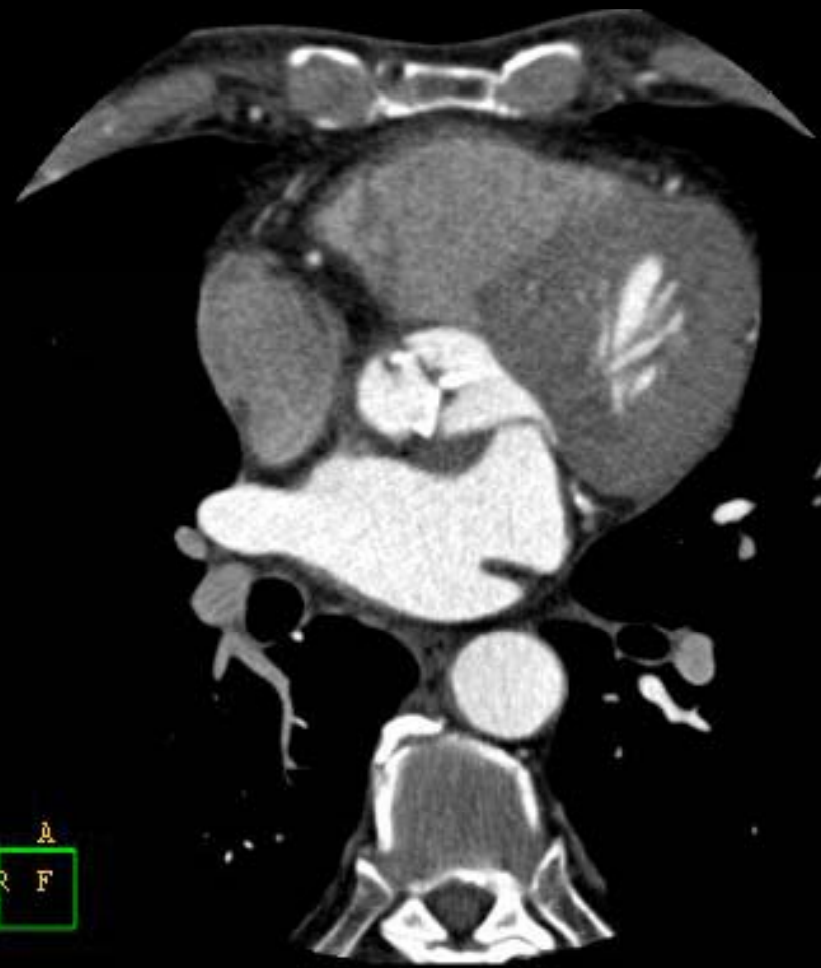L 1, UU

R

A
R F

PHILIPS

P



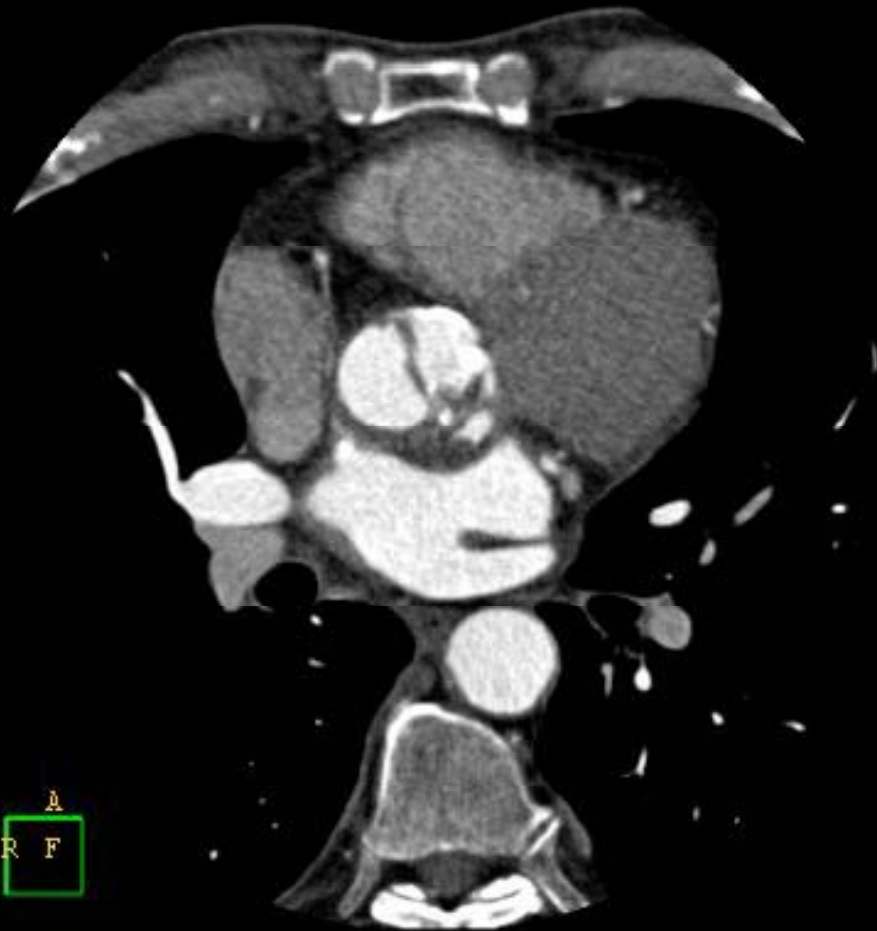Z 1,00

R

A
R F

PHILIPS

P



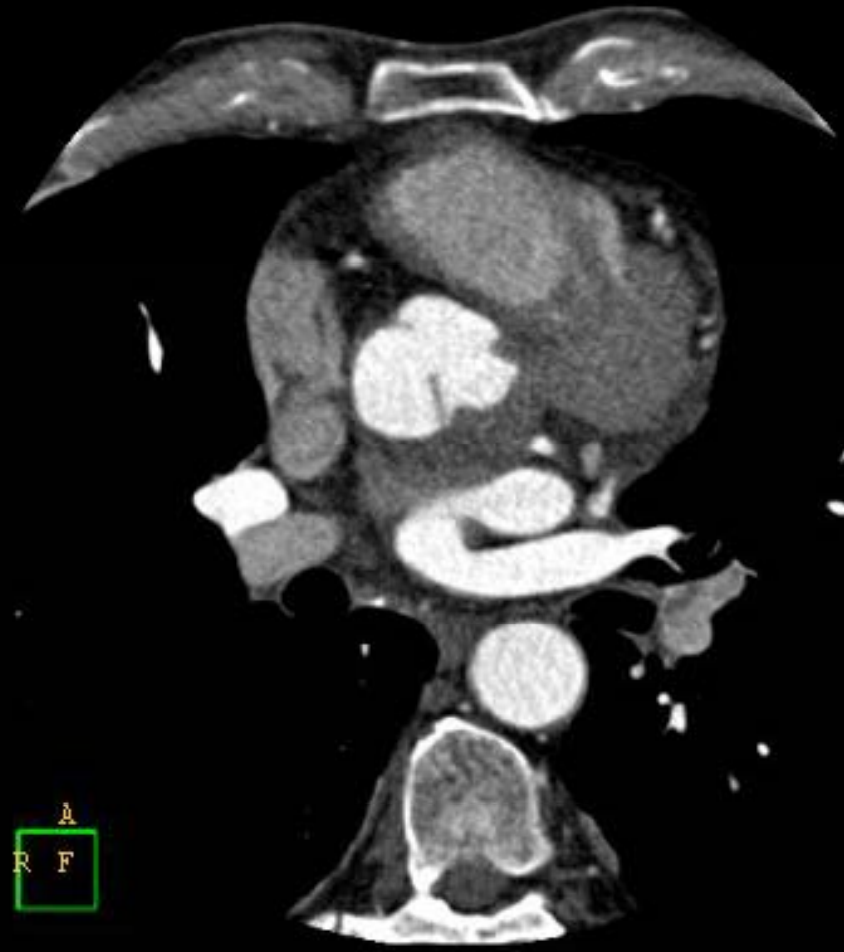L 1,00

R

A
R F

PHILIPS

P



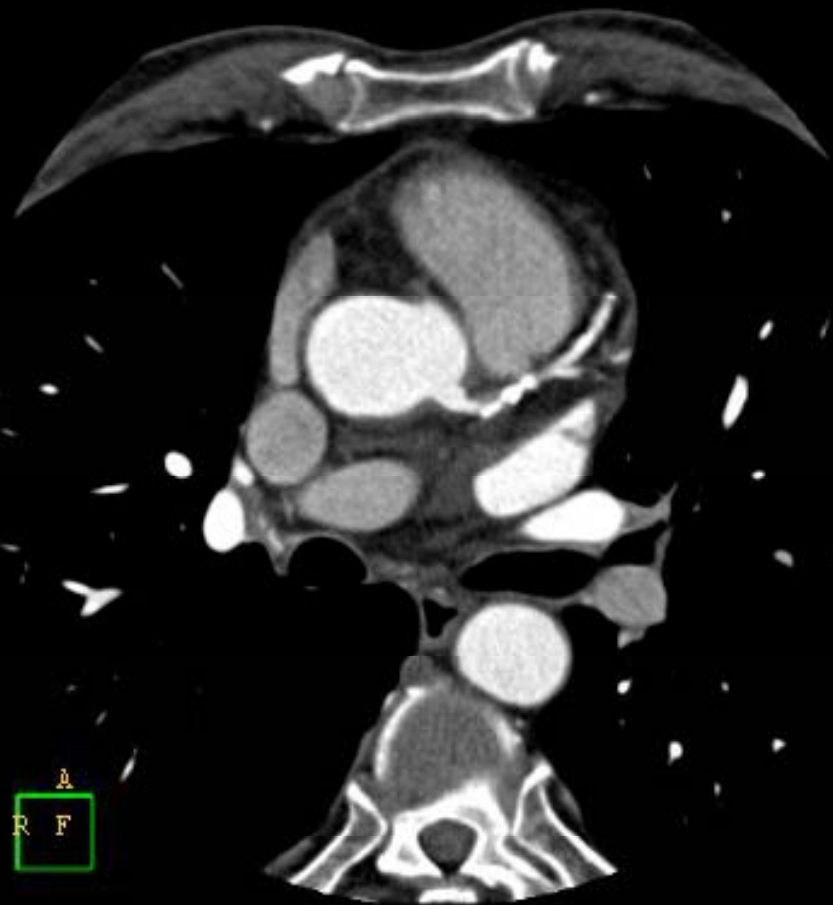
Z 1,00

R

A
R F

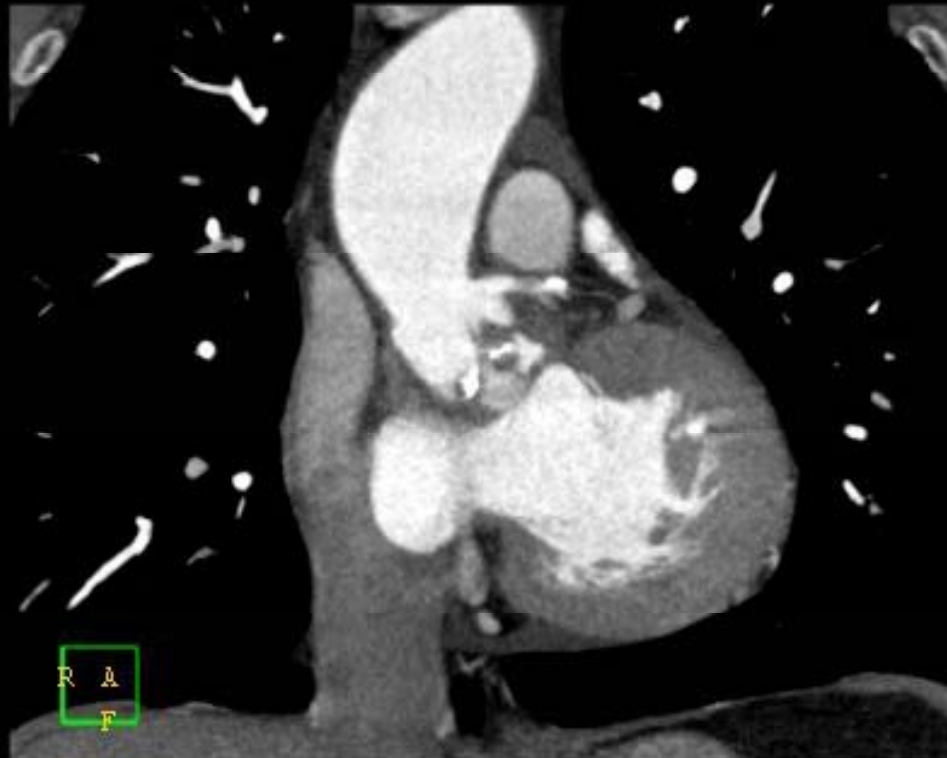PHILIPS

P



L 1,00

R

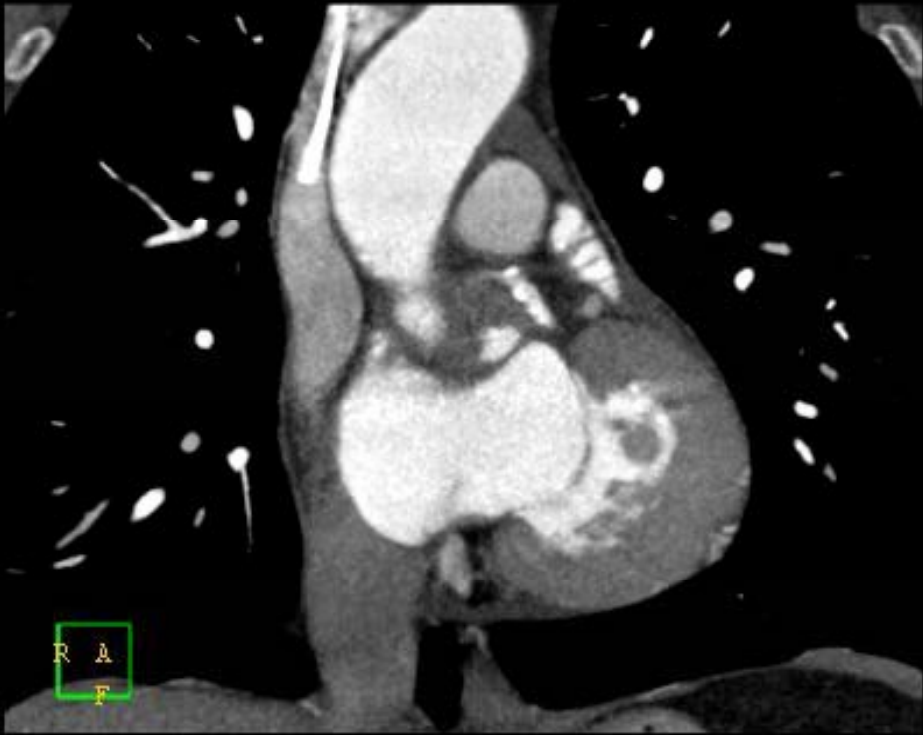

PHILIPS

F

L 1, UU

R

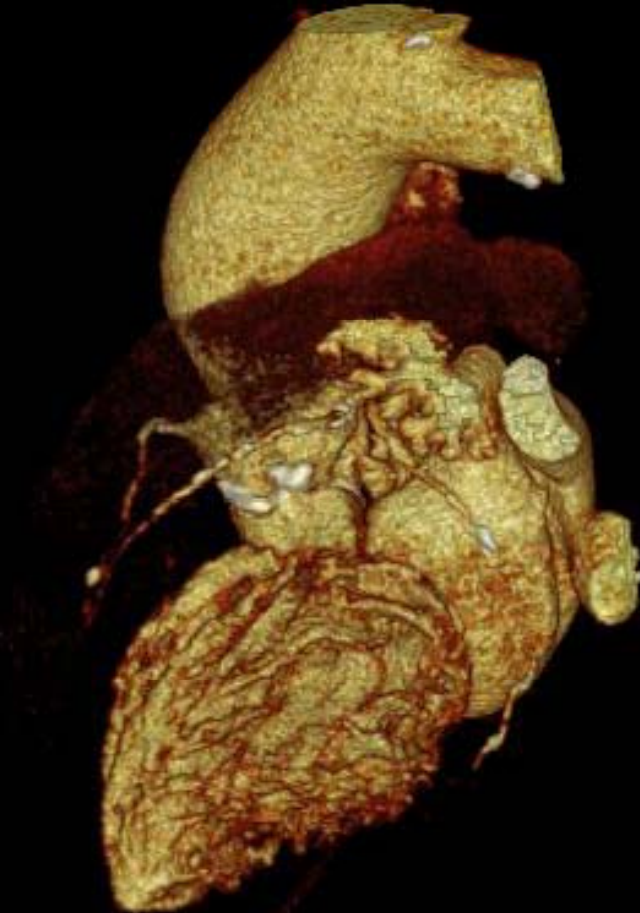


R
A
F

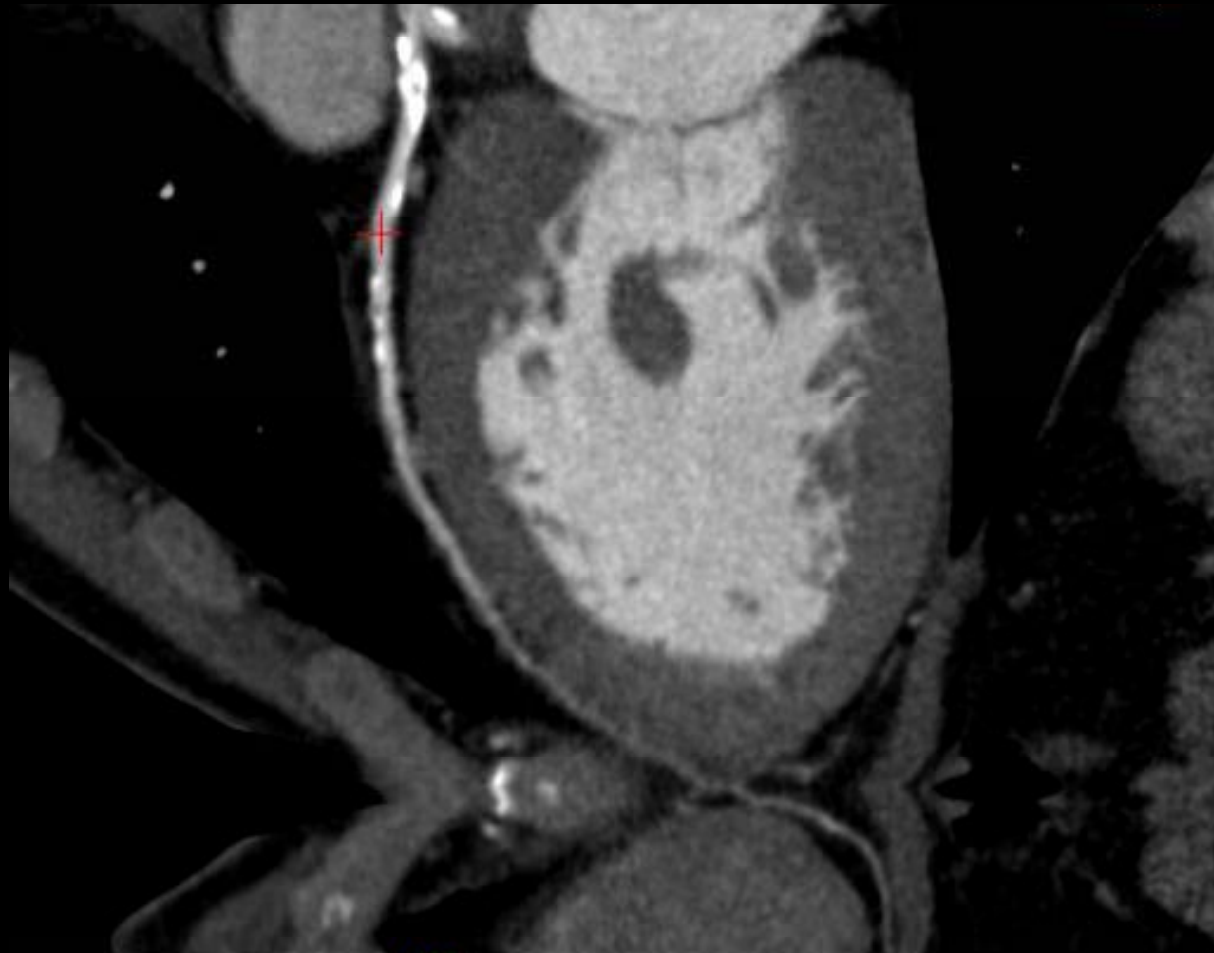
PHILIPS

F

L 1,00



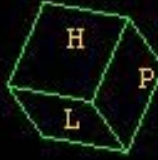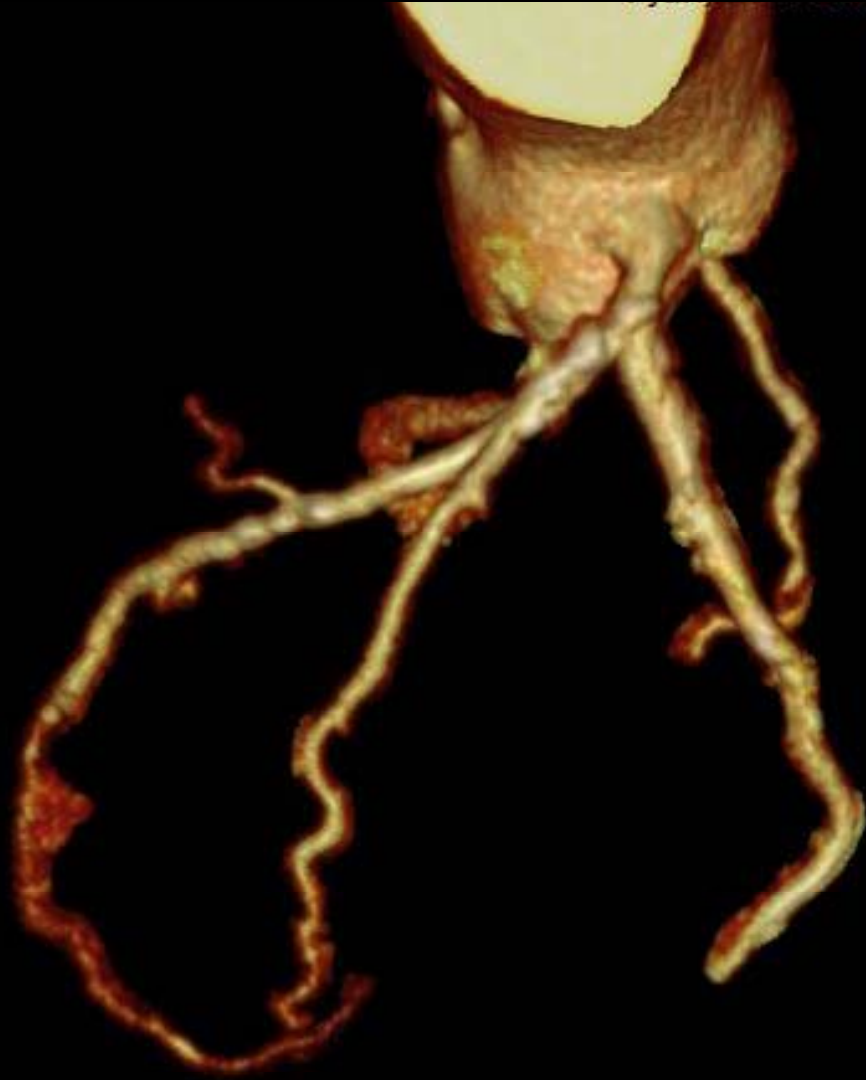PHILIPS



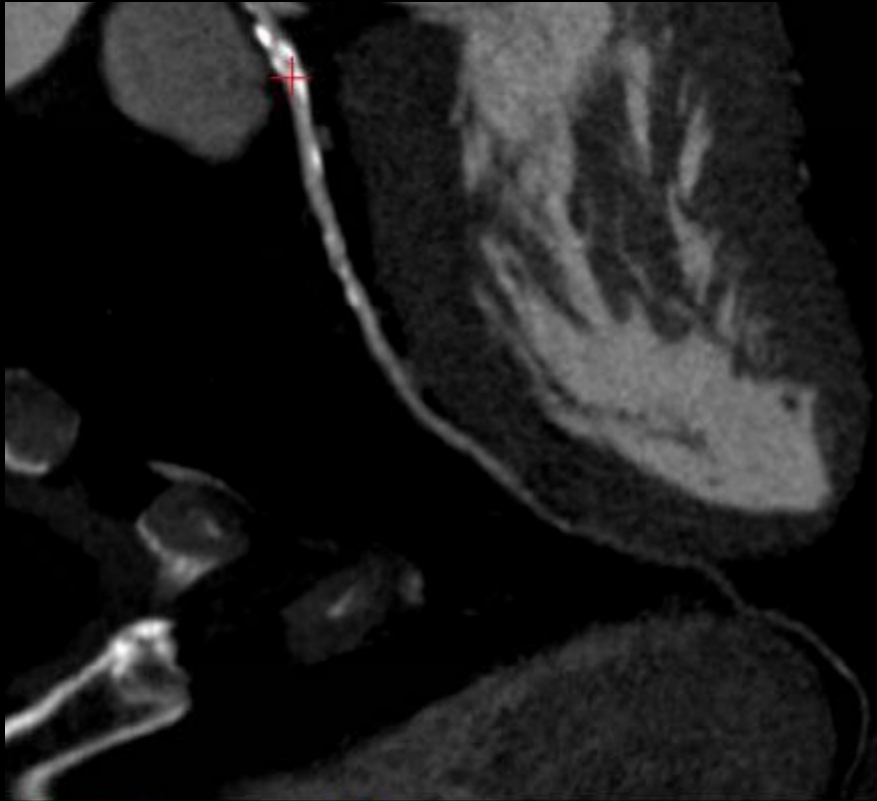
PHILIPS

DAI

Z 1,00

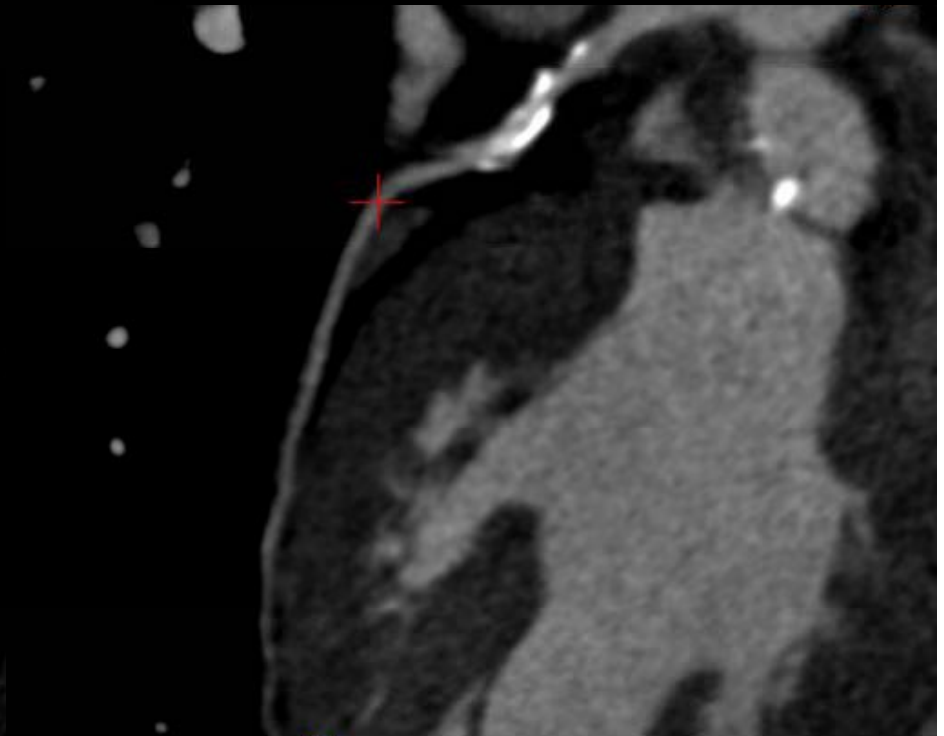


PHILIPS



PHILIPS

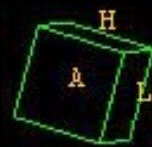DAI



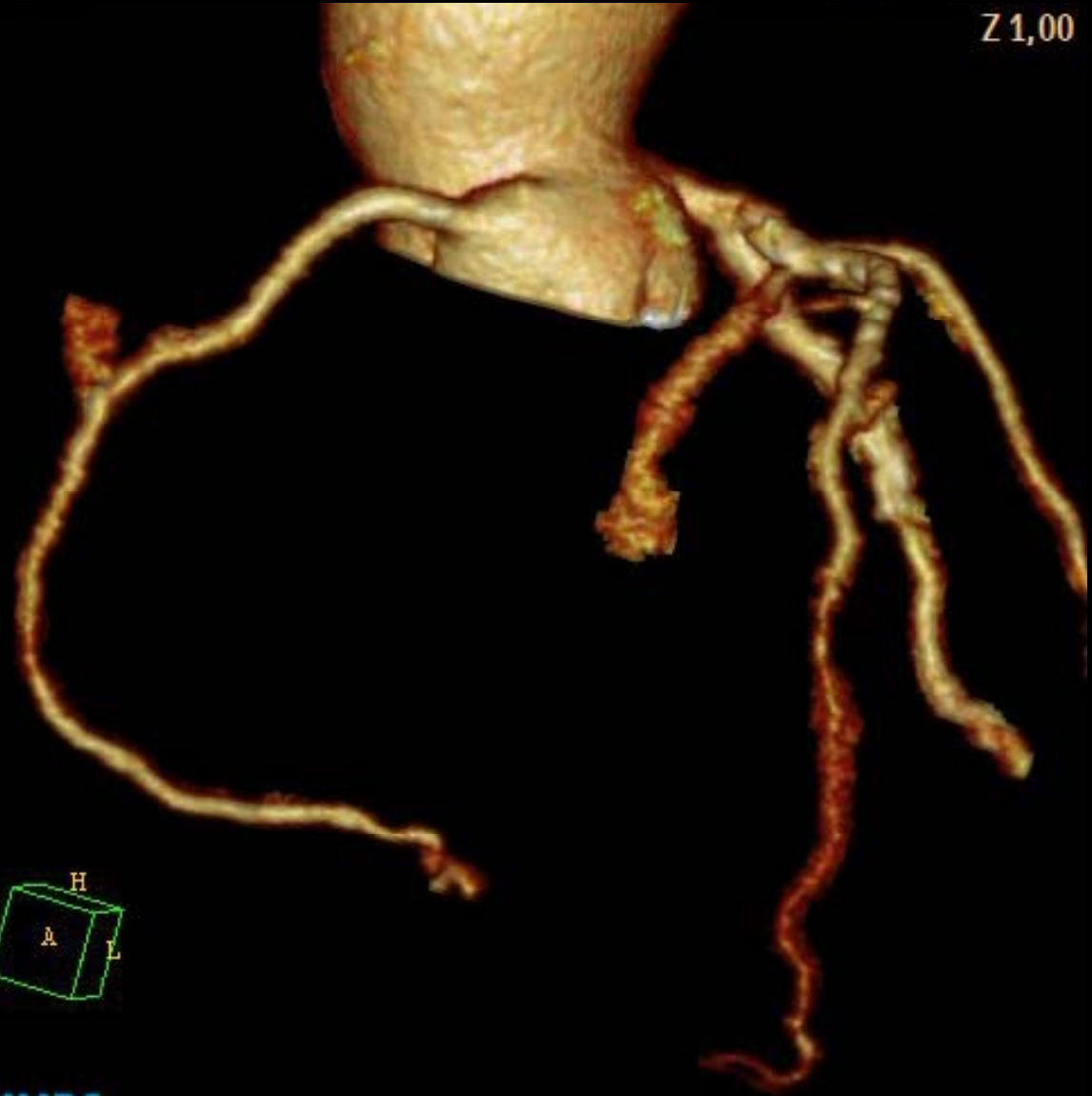
PHILIPS

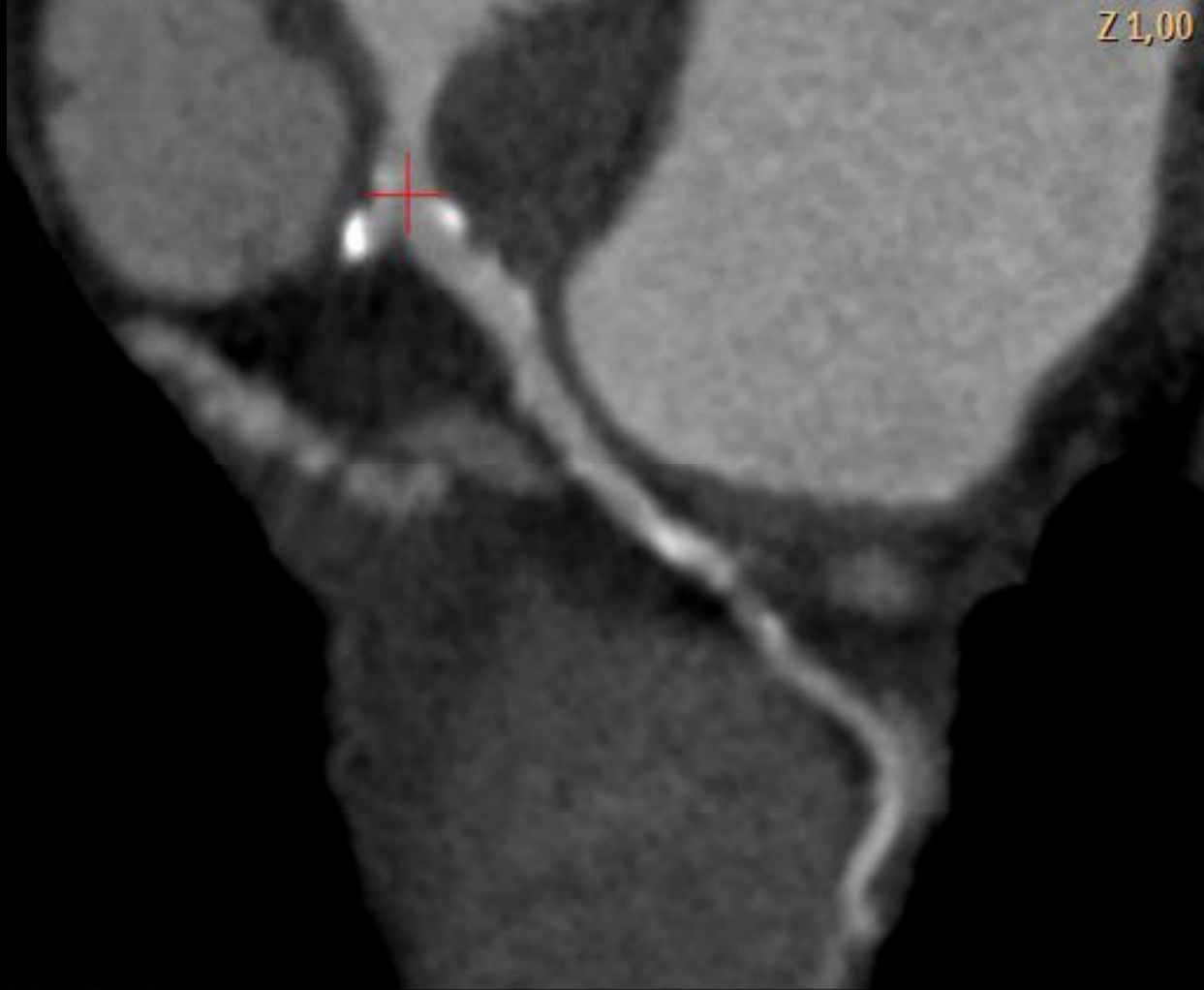
D1

Z 1,00



PHILIPS





Z 1,00

PHILIPS